

# The Development of the Spermatophoric Mass of the Rock Lobster, *Parribacus antarcticus* (Lund)<sup>1</sup>

DONALD C. MATTHEWS<sup>2</sup>

## INTRODUCTION

THE LITERATURE on the spermatophores of the tribe Scyllaridea is both superficial and scattered. Although cursory accounts of the extruded mass have appeared for both the Palinuridae and the Scyllaridae, few thorough histological studies have been made. This paper proposes to extend the knowledge of the biology of the common Hawaiian scyllarid, *Parribacus antarcticus* (Lund), through an account of its spermatophoric development.

Although Calman (1909: 290) in discussing the spermatophores of Crustacea fails to mention specifically the spermatophores of the Palinuridae [*sens. lat.*], he does state that in most Macrura the spermatozoa are enclosed in a sheath, forming a continuous cord-like mass. Moreover, he (*loc. cit.*) states that, "In *Scyllarus* and in the Anomura this is broken up into separate spermatophores attached by one end in a row on a strip of membrane."

Andrews (1912: 178), in referring to the spermatophoric mass of *Panulirus argus* Latreille, states:

When cut the interior was white and full of holes or tubes. It suggested a very stiff cheese, but the minute cavities were not closed vesicles but short tubes . . . a careful examination of sections shows the short, tubular and somewhat branched cavities to be about one half millimeter in diameter and 1 or two long, separated by very fine walls of the dense white rubber-like material . . . the enveloping mass is white except on the surface where it is more or less black or grey according, apparently, to the length of exposure to water.

Although the change in consistency and color conforms to that observed by the author in the extruded mass of *Panulirus penicillatus* (Oliver), the observed "tubular cavities" were probably merely the result of sections cut through a highly contorted, continuous tube (Matthews, 1951: 365, fig. 10).

Andrews' description (*op. cit.*, 183) of the external spermatophoric mass of *Parribacus antarcticus* is adequate, but again his reference to an "internal . . . matrix enclosing tubular cavities" is, as will be shown subsequently, erroneous.

Allen (1916), Fasten (1917), and Wilson (1948) described the change of color and consistency in the extruded spermatophoric mass of *Panulirus interruptus*, but did not investigate its development within the vas deferens. The observations of Crawford and De Smidt (1923) on *Panulirus argus* were also limited to the extruded spermatophoric mass.

The nonpedunculate spermatophore of *Panulirus penicillatus* (Oliver) (*vide* Matthews, 1951) resembles the spermatophores of the Macrura, but apparently no published accounts have verified Calman's statement (*op. cit.*) regarding the pedunculate spermatophores of the Scyllaridae.

## METHODS AND TECHNIQUES

Twenty sexually mature *Parribacus antarcticus* (Lund) obtained from the Honolulu Aquarium during May, June, and July, 1952, were used in this study. Of the 18 male reproductive systems dissected, 6 were used to study the nature of the testes and the coiled vasa deferentia, 8 were vitally stained, and 4

<sup>1</sup> Contribution No. 41, Hawaii Marine Laboratory.

<sup>2</sup> Department of Zoology and Entomology, University of Hawaii. Manuscript received December 22, 1952.

were serially sectioned. Of the two females obtained, only one possessed a spermatophoric mass; this was dissected and studied.

All dissections were made on living, non-anesthetized specimens immersed in sea water. The carapace was opened quickly, and the internal organs overlying the reproductive system were removed. The testis and coils of the vas deferens were then studied and sketched.

Two methods were employed in vital staining with aqueous solutions of neutral red and toluidin blue: (1) The stains were injected into the enlarged distal portion of the vas deferens (Fig. 1*d*) and allowed to permeate

its contents proximally to the testis; (2) the vas deferens was removed from the body and placed in the stains. Both neutral red and toluidin blue were used in concentrations of 1:1,000 to 1:10,000. For the injection technique, solutions of approximately 1:1,000 to 1:5,000 were used; for the immersion technique, solutions of approximately 1:10,000 were used, and the vas deferens was allowed to remain in the stain from 10 to 30 minutes. The vas deferens was then removed from the stain and placed in sea water for subsequent study. Because injection tends to distend the walls and causes the stains to permeate the surrounding tissues, this technique was later abandoned in favor of the more easily controlled immersion method.

The walls of the vasa deferentia were then teased open under a dissecting microscope and the vitally stained contents studied and drawn.

The vasa deferentia to be sectioned were removed quickly and placed in Bouin's fluid. After fixation, the tissues were washed in alcohol (70 per cent) and either cleared in dioxan and embedded in Tissuemat, cleared in toluene and embedded in Tissuemat, or placed in dioxan, cleared in methyl-benzoate (1 per cent celloidin added), washed in xylene, and embedded in Tissuemat (54–56°C.). None of these modifications was completely satisfactory for all regions of the vas deferens. All gave good preparations for sectioning the small proximal regions and poor preparations for sectioning the large, distal regions. This was due to the presence of the matrix (Fig. 10*c*) which upon dehydration had become extremely brittle. The distal region of the vas deferens could be sectioned only after immersing the block in water, although this resulted in some swelling of the connective tissue. The tissues were sectioned at 10 microns, stained in standard alumhaematoxylin, and counterstained with eosin.

The writer wishes to thank Mr. Spencer Tinker for supplying the specimens and Mr. James Park for making the illustrations.

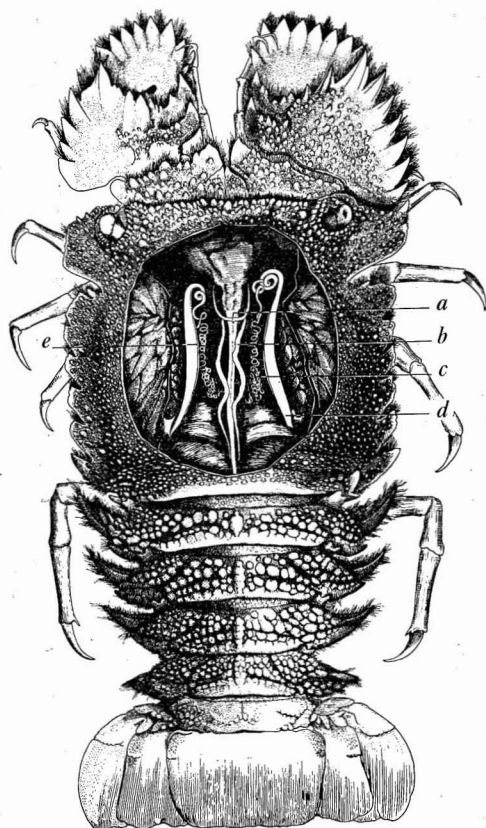


FIG. 1. Dissection of a mature male *Parribacus antarcticus* (Lund), drawn to show the position of the reproductive system. *a*, Transverse bridge; *b*, testis; *c*, coiled, proximal portion of vas deferens; *d*, straight, distal portion of vas deferens; *e*, hyaline line. (0.6X.)

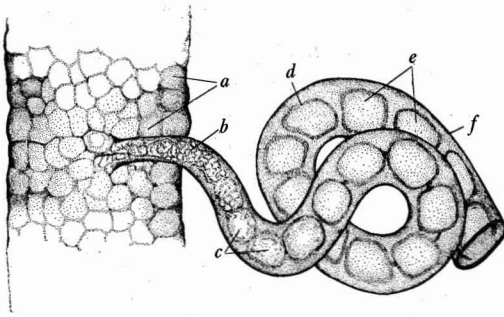


FIG. 2. A small portion of the testis and proximal vas deferens showing results of toluidin blue immersion technique. *a*, Sacculi; *b*, undifferentiated spermatogenic substance; *c*, moniliform portion; *d*, capsule of ampulla; *e*, distinct ampullae; *f*, thin wall of vas deferens. (15 $\times$ .)

#### DISCUSSION

The testes (Fig. 1*b*), when freed from overlying tissues, resemble those of *Panulirus penicillatus* (Matthews, 1951: 360) in that they form an elongate H, the right and left sides joined by a transverse bridge (*a*) just posterior to the junction of the pyloric region of the stomach to the intestine. As in *P. penicillatus*, the testes lie contiguous to the digestive tract. Occasionally one, less frequently both, of the portions of the testes anterior to the bridge bifurcate, although the posterior region is unaltered. The dissecting microscope reveals the testis as a highly coiled, continuous, thin-walled tube into which innumerable small

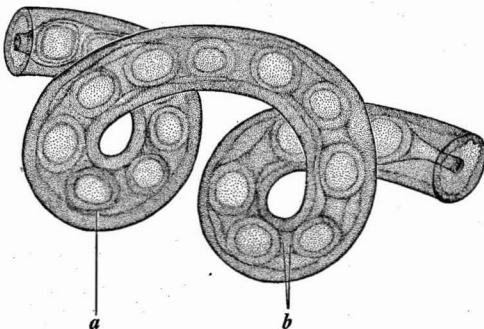


FIG. 3. A small portion of the vas deferens immediately distal to the region illustrated in Figure 2, showing results of toluidin blue immersion technique. *a*, Secretion which envelops the already encapsulated ampullae; *b*, sheath between successive ampullae. (15 $\times$ .)

sacculi open (Fig. 2*a*). The sacculi of different regions appear indistinguishable as to number and size. Both testes are enveloped by a delicate mesentery and penetrated by numerous blood vessels.

The vas deferens (Fig. 1*c*) which emanates from the testis is an extremely small, highly coiled tube which, increasing in diameter distally, finally emerges as a large tube (*d*) opening on the coxopodite of the fifth periopod. A hyaline line (*e*) traverses most of the length of the otherwise chalky, opaque tube, marking the position of the internal typhlosole (Fig. 10*d*). This hyaline line is prominent only in the distal enlarged portion (Fig. 1*d*). The

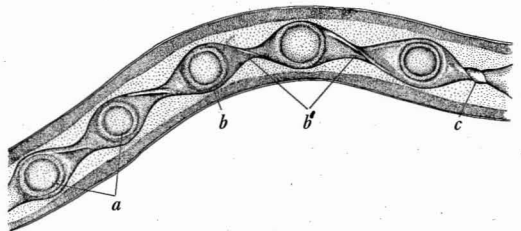


FIG. 4. Diagram of a small portion of the vas deferens immediately distal to the region illustrated in Figure 3, showing the results of immersion technique. *a*, Successive encapsulated ampullae; *b*, sheath surrounding encapsulated ampulla; *b'*, ribbon-like sheath between successive ampullae; *c*, twisted, ribbon-like sheath. (15 $\times$ .)

numerous coils of the proximal portion are not constant either as to number or direction of their turns, as none of the vasa deferentia studied was identical.

All regions of the vas deferens fail to exhibit muscular contractions and are quiescent even when exposed quickly. There were no intermittent contractions which are so characteristic of certain vasa deferentia. Whereas the persistent mobility of the vas deferens of *Dardanus asper* (Matthews, 1953: 258) may be related to its stamina, the apparent immobility of the vas deferens of *P. antarcticus* may be related to its debility. The cessation of contractions in the altered, exposed vas deferens obscures the mechanical aspect of spermatophoric development. Vital staining is there-

fore invaluable in discerning the effects of contractions in the unaltered vas deferens.

Figure 2 illustrates the results of immersing a small portion of the testis and the proximal region of the vas deferens in toluidin blue. Here the thin wall of the vas deferens (*f*) affords rapid penetration of the stain, and the absence of the matrix (Fig. 10*c*) makes clear the developing spermatophore. The undifferentiated spermatogenic substance (Fig. 2*b*) is seen as it enters the vas deferens. As it traverses the vas deferens, this undifferentiated spermatogenic substance becomes moniliform (*c*) and, acquiring a capsule (*d*), separates into distinct ampullae (*e*).

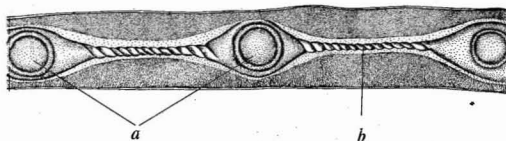


FIG. 5. Diagram of a dissected portion of the vas deferens immediately distal to the region illustrated in Figure 4, showing the results of immersion technique. *a*, Widely separated encapsulated ampullae; *b*, highly twisted, ribbon-like sheath. (15 $\times$ .)

Figure 3 illustrates the results of the immersion technique on a small portion of the vas deferens immediately distal to the region illustrated in Figure 2. A new sheath (*a*) now envelops the already encapsulated ampullae and occupies the space between successive ampullae (*b*).

The results of the immersion technique on a small portion of the vas deferens immediately distal to the region illustrated in Figure 3 are shown in Figure 4. The successive ampullae (*a*) are now more widely separated. The sheath (*b*) which envelops the already encapsulated ampullae is thin and between successive ampullae is now ribbon-like (*b'*). In the distal portion of this region the ribbon-like sheath connecting successive ampullae is twisted (*c*).

Figure 5 is a diagram of a dissected portion of the vas deferens immediately distal to Figure 4. The ampullae (*a*) are widely separated

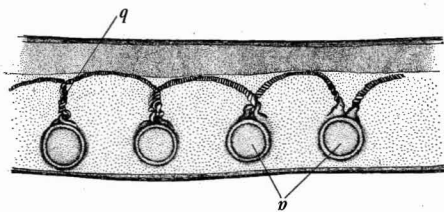


FIG. 6. Diagram of a dissected portion of the vas deferens distal to the region illustrated in Figure 5. *a*, "Elevated" ampullae; *b*, entwined, twisted ribbons. (15 $\times$ .)

and the connecting sheath (*b*) is more highly twisted.

A diagram (Fig. 6) of a dissected portion of the vas deferens distal to Figure 5 shows the ampullae (*a*) less widely separated and "elevated" by the entwining of their already twisted connecting sheaths (*b*).

Serial sections substantiate what vital staining has so far revealed and enable one to determine the origin of the various secretions. Figure 7 is a cross section through the vas deferens in the region indicated by *b* of Figure 2. The undifferentiated spermatogenic mass (*a*) occupies the almost circular lumen (*b*). The wall of the vas deferens is here composed

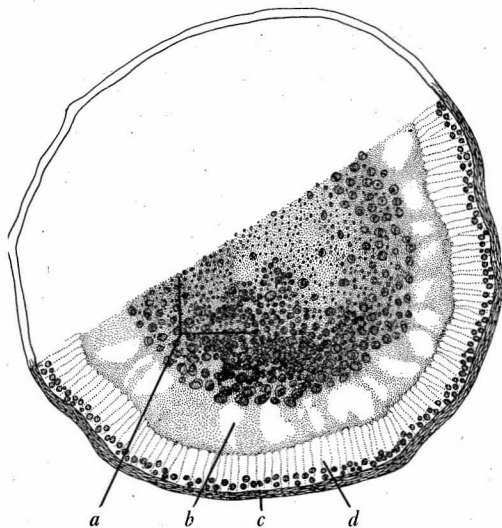


FIG. 7. A cross section through the vas deferens in the region indicated by *b* of Figure 2. *a*, Undifferentiated spermatogenic mass; *b*, circular lumen; *c*, wall of vas deferens; *d*, epithelial layer. (134 $\times$ .)

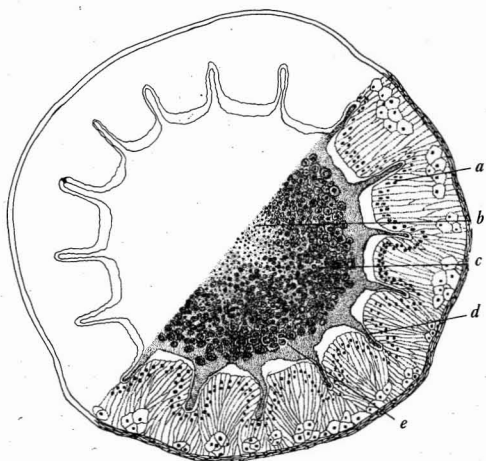


FIG. 8. A cross section through the vas deferens in the region indicated by *c* of Figure 2. *a*, Crypt-like fold of the epithelium; *b*, spermatids; *c*, secondary spermatocytes; *d*, capsule secretion; *e*, primary spermatocytes. (106 $\times$ .)

of a thin muscular and connective tissue layer (*c*), and a thin layer of epithelium (*d*). In Figure 8 the spermatophoric capsule is being laid down by a secretion (*d*) of the crypt-like folds of the epithelium (*a*). It is significant that spermatogenesis is taking place. Primary spermatocytes (*e*), secondary spermatocytes (*c*), and spermatids (*b*) are clearly discernible.

Figure 9, a cross section through the vas deferens in the region indicated by *a* of Figure 3, shows the secretion of the sheath (*b*) around the already encapsulated ampulla (*c*).

Figure 10 is a stereogram of the vas deferens through the region indicated by *d* of Figure 1. The ampullae (*a*) are "elevated" and the already twisted connecting ribbon-like sheaths are entwined (*b*). The matrix (*c*), the copious secretion of the typhlosole (*d*), has forced the spermatophores to lie opposite the hyaline line (*e*).

Figure 11 is a drawing of a portion of a female sternum (*a*) and a partially dissected spermatophoric mass. The hard, darkened outer portion of the matrix (*b*) envelops the less hardened matrix (*c*) which contains the ampullae (*d*) attached to doubly twisted peduncles.

The undifferentiated sperm mass emanates from the testis probably because of the continuous activity of the germinal epithelium lining the sacculi. In the proximal portion of the vas deferens, not more than 4 or 5 millimeters long, this undifferentiated spermatogenic material is both moved along and molded into a continuous moniliform mass, presumably by the muscular contractions of the wall. In this same region of the vas deferens the crypt-like folds of the epithelium produce a secretion which forms the thick capsules of the now distinct ampullae.

As the encapsulated ampullae traverse the vas deferens, the epithelium produces another secretion, the sheath, which both surrounds the already encapsulated ampullae and fills the intervening spaces. Less than 1 centimeter of the proximal vas deferens is traversed before the portions of this sheath lying between adjacent ampullae are compressed into a thin, delicate ribbon, probably by contractions of the wall of the vas deferens. Because of the immobility of the dissected vas deferens, the process was not observed.

The chalazal twisting of the connecting ribbons probably is due to the rotations of the

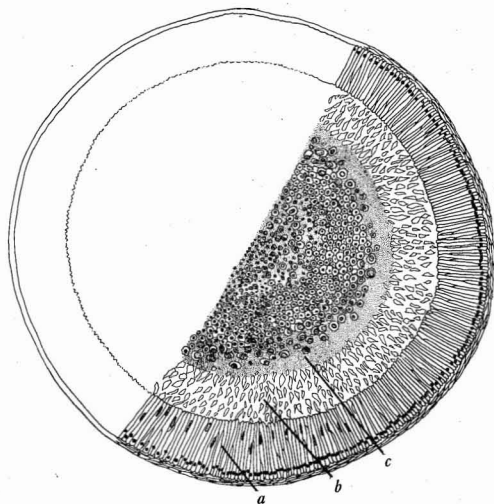


FIG. 9. A cross section through the vas deferens in the region indicated by *a* of Figure 3. *a*, Epithelium; *b*, sheath secretion which surrounds the encapsulated ampullae; *c*, capsule. (125 $\times$ .)



ampullae as the coils of the proximal region of the vas deferens are traversed. The "drawing together" of the ampullae probably is also the result of the shortening of the ribbons due to this twisting. Moreover, the entwining of the already twisted ribbons to form the stalk or peduncle is also a result of this process.

The secretion of the typhlosole now surrounds the already formed spermatophores and by its accumulation forces the continuous, pedunculate spermatophores against the wall of the vas deferens opposite the hyaline line.

As the spermatophores traverse and finally accumulate in the enlarged distal portion of the vas deferens, the process of spermatogenesis is completed. The primary spermatocytes have undergone two successive divisions, and the spermatids have metamorphosed into mature spermatozoa.

It is at this stage of development that the spermatophoric mass is placed on the sternum of the female and, as described by Andrews (*op. cit.*), darkens and hardens when it is exposed to sea water. The dissected spermatophoric mass reveals not a series of tubular cavities but a continuous thread-like ribbon (or two ribbons if both vasa deferentia have participated) from which the pedunculate spermatophores extend.

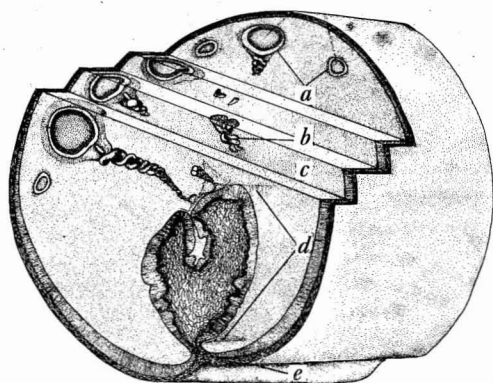


FIG. 10. Stereogram of the vas deferens in the region indicated by *d* of Figure 1. *a*, "Elevated" ampullae; *b*, entwined, twisted ribbons; *c*, matrix; *d*, typhlosole; *e*, hyaline line. (25X.)

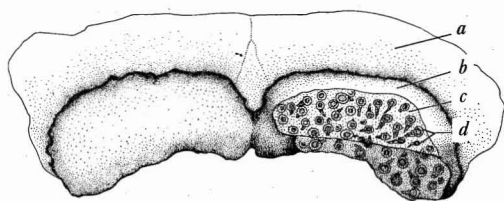


FIG. 11. A partially dissected spermatophoric mass taken from the sternum of the female. *a*, Portion of sternum; *b*, hard, dark portion of matrix; *c*, soft, light portion of matrix; *d*, ampullae attached to doubly twisted peduncles. (3.5X.)

It should be recalled that only one female was observed which possessed the spermatophoric mass. The actual process of sperm liberation was not observed, but the scratched, hardened matrix, together with the specialized claws (*vide* Andrews, *op. cit.*), suggest a mechanical method.

The results of this investigation may lead to speculations on the systematic position of the Scyllaridae. Although the spermatophores of *Parribacus antarcticus* are intermediate between those of the nonpedunculate spermatophores of a palinurid (*Panulirus penicillatus*) and the pedunculate spermatophores of a pagurid (*Dardanus asper*), an inference that *Parribacus antarcticus* is intermediate between these forms is not warranted. Anatomical, embryological, and serological evidence should accompany such spermatophoric evidence, and this should be drawn from many species representing many genera.

The present study on the spermatophores of *P. antarcticus* should serve to question the interpretation placed on the function of the peduncle. The origin of the seemingly significant peduncle may have been only the fortuitous occurrence of mechanical and physiological activities of the vas deferens with little regard for the elevation of the ampullae and the subsequent dispersal of the spermatozoa. Certainly, in *P. antarcticus* the peduncle serves no such useful purpose, inasmuch as the hard enveloping matrix prevents the ampullae from being held "aloft."

## REFERENCES

- ALLEN, B. M. 1916. Notes on the spiny lobster (*Panulirus interruptus*) of the California coast. *Calif. Univ., Pubs., Zool.* 16(12): 139-152.
- ANDREWS, E. A. 1912. Spermatophores and specialized claws in *Palinurus* and *Parribacus*. *Zool. Jahrb., Suppl.* 15 [vol. 3]: 177-190.
- CALMAN, W. T. 1909. Crustacea. In: *A treatise on zoology*. [Sir Ray Lankester Ed.] Part VII, fasc. 3, 332 pp. A. & C. Black, London.
- CRAWFORD, D. R., and W. J. J. DE SMIDT. 1923. The spiny lobster, *Panulirus argus* of southern Florida—its natural history and utilization. *U. S. Bur. Fisheries, Bul.* 38: 281-310.
- FASTEN, N. 1917. Male reproductive organs of Decapoda, with special reference to Puget Sound forms. *Puget Sound Mar. Sta., Pub.* 1: 285-307.
- MATTHEWS, D. C. 1951. The origin, development, and nature of the spermatophoric mass of the spiny lobster, *Panulirus penicillatus* (Oliver). *Pacific Sci.* 5(4): 359-371.
- 1953. The development of the pedunculate spermatophore of the hermit crab, *Dardanus asper* (De Haan). *Pacific Sci.* 7(3): 255-266.
- WILSON, R. C. 1948. A review of the Southern California spiny lobster fishery. *Calif. Fish and Game* 34(2): 71-80.